

## Efficacy of ORAL CHELATION in Carotid Artery Disease : A Case report :

**Dr. A. Rajasimha MD. PhD (Cardiology)**

**Fellow of National Institute for Education & Research ( FNIER )**

**Consultant in Non invasive & Preventive Cardiology**

**Chief of Clinical Preventive Cardiovascular Research.**

**Simha Heart Foundation**

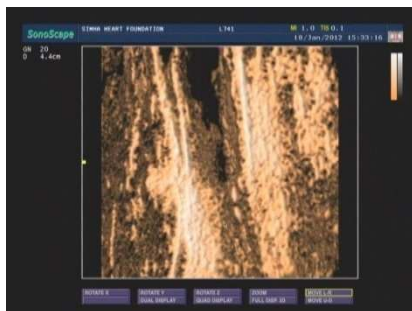**First Hi-tech Heart Centre of Mysore City.**

**Mysore, Karnataka, South India.**

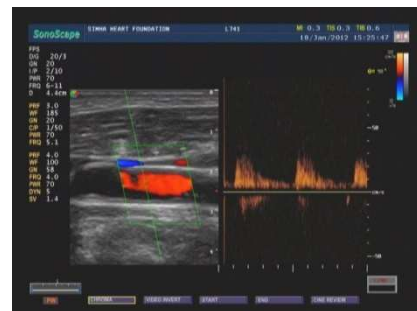
### Summary of patient's data

Mr. K 60 year old Male a Chronic Smoker / Hypertensive / Non-Diabetic presented to Simha Heart Foundation with symptoms of recurrent transient loss of power in the right half of the body of Four weeks duration. His arrival BP was 170 / 100 mm Hg. ECG was within normal limits with Sinus Rhythm. Blood Chemistry revealed Abnormal Lipid profile. MRI Brain & SPECT Brain were unremarkable. 4D Colour Doppler Echo showed Normal valves / LVH / Good BVF / No RWMA / Normal PAP / No LV Clot. 4D Colour Doppler Flow Mapping of Carotids showed sub-total occlusion of LCCA with calcified long segment mixed plaquing with markedly low amplitude attenuated flow signals from LCCA. A diagnosis of Transient Ischemic Attack ( TIA ) of Left Carotid system with impending right Hemiplegia was made.

### Pre-Oral Chelation



Picture 1a



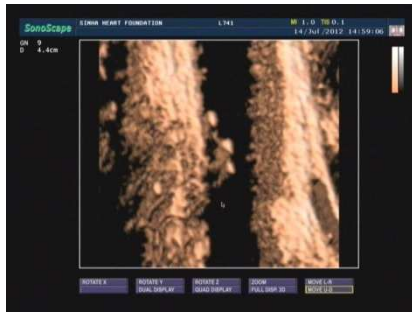Picture 1b

Picture 1a shows 4D CDFM of LCCA with sub-total occlusion by calcific mixed plaquing & Picture 1b shows markedly attenuated low amplitude flow signals derived from LCCA.

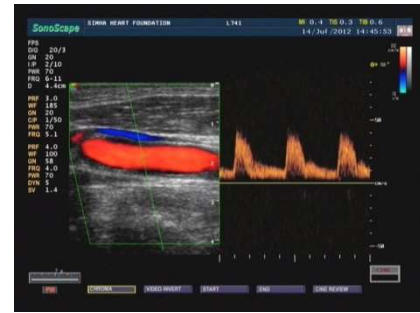
### Treatment Protocol :

Patient was put on Anti-HTN / Anti-platelets medications. Also patient was advised Oral Chelation ( Cardio Clean ). Patient was put on one sachet ( EDTA 1000 mg ) once in 2 days for 3 months & then one sachet once in 3 days for next 3 months with a close monitoring of his Renal Profile & Hematological indices. By 4 weeks patient's TIA got abolished & after 6 months of oral Chelation a repeat 4D colour Doppler Flow Mapping of Carotids showed total opening up of LCCA with an excellent flow signals. Renal parameters & BT / CT / PT remained unaltered.

## Post-Oral Chelation



Picture 2a



Picture 2b

Picture 2a by 4D CDFM shows near normalization of lumen of LCCA by significant plaque regression & Picture 2b shows excellent flow signals derived from LCCA.

### Remarks :

Oral Chelation using Cardio Clean appears to be a very effective plaque regressing treatment & patient Mr. K's results by 4D Colour Doppler Flow Mapping both Pre & Post Cardio Clean is an affirmative proof to demonstrate the efficacy & effectiveness of Oral chelation.

### Observations :

1. Cardioclean is a food supplement containing Oral EDTA
2. It is well tolerated by the patients with no GI disturbances
3. The dose can be titrated according to the severity of plaques
4. It has a satisfactory safety profile with reference to Renal Parameters & BT / CT / PT
5. Excellent compatibility with other standard Cardiac medications.

### Caveat :

Cardioclean should not be used by patients on their own or sold as OTC medication though it is food supplement since the product may become abused by lay public as well substituted by spurious drug manufacturers leading to any systemic complication.

---